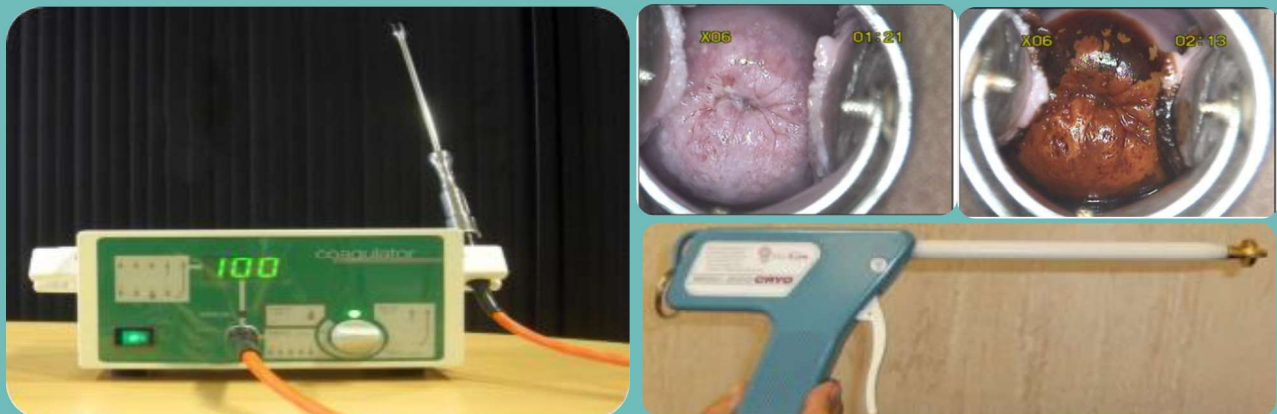

# ICMR- National Institute of Cancer Prevention and Research

## *Training Manual on Cervical Cancer Screening using* **Visual Inspection with Acetic Acid**



**ICMR- National Institute of Cancer Prevention and Research**

I – 7, Sector – 39, Noida, Uttar Pradesh– 201301 (India)

Phone: +91-120 -2446938 Fax: +91-120-2579473

Websites: [www.nicpr.res.in](http://www.nicpr.res.in) | [www.cancerindia.org.in](http://www.cancerindia.org.in)



*Training Manual on Cervical Cancer Screening using*  
**Visual Inspection with Acetic Acid (VIA)**

---

**Contributors:**

Dr. Roopa Hariprasad  
Dr. Kavitha Dhanasekaran  
Prof. Ravi Mehrotra  
Dr. Shalini Singh

# **Training Manual on Cervical Cancer Screening using Visual Inspection with Acetic Acid**

**This training manual is drafted by and is copyright of ICMR-National  
Institute of Cancer Prevention and Research, Noida**

**THIS IS NOT FOR SALE**

***First Edition: Printed in July 2019***

© No part of this document may be reproduced in any form by photo, photo print, microfilm, or any other means without prior approval of **ICMR-National Institute of Cancer Prevention and Research, Noida.**



## ABOUT THIS MANUAL

Government of India is undertaking a population-based cancer screening of three common cancers in the country; oral, breast and cervical cancer. According to the operational guidelines, cervical cancer screening will be done using Visual Inspection with Acetic acid (VIA) by ANMs and staff nurses at the Primary Health Centre (PHC) level.

This manual is intended mainly for ANMs and staff nurses working at PHCs. It covers VIA test in detail, the interpretation of the test with pictorial representation of each condition. This manual also gives information on the ablative treatment modalities like cryotherapy and thermal ablation that can be used in “Screen and Treat Approach” which is the recommended management strategy for eligible screen test positive individuals in a single visit. This strategy minimizes the loss to follow up and avoids unnecessary overloading of the higher referral facilities.

Gynecologists and Lady medical officers trained in cervical cancer screening and management have been identified as the master trainers. ANMs and staff nurses will undergo a comprehensive 10 days training at identified medical colleges or district hospitals where the trainees will be imparted theoretical knowledge on principle of VIA test, procedure of carrying out the test, appropriate interpretation and reporting of the test and practical skills like insertion of speculum, performing VIA test, performing ablative treatment methods which will make them proficient in screening and treatment of precancerous lesions using ablative methods.

To be certified as VIA trained, the trainee needs to score at least 70% in the knowledge and 80% in the skill assessment at the end of the training. The objective is to create a work force that will be confident and competent to perform cervical cancer screening at PHC and effectively bring down the burden of this preventable cancer in the country!

ICMR-NICPR

## TABLE OF CONTENTS

Contents	Pg No.
<b>Chapter 1: Visual inspection with acetic acid (VIA)</b>	<b>1</b>
Principle of VIA test	1
Gross anatomy of the uterine cervix	2
Microscopic anatomy	2
Instruments and materials required	4
Preparation of 5% acetic acid	4
Procedure of VIA test	5
Reporting the outcome of VIA /interpretation of VIA test	6
Images of VIA test Negative	7
Images of VIA test Positive	8
Images of VIA test positive, suspicious of cancer	8
<b>Chapter 2: Visual Inspection using Lugol's Iodine (VILI):</b>	<b>9</b>
Principle of VILI test	9
Instruments and materials required	9
Preparation of Lugol's iodine	9
Procedure of VILI test	9
Reporting the outcome of VILI /interpretation of VILI test	10
Images for VILI test Negative	10
Images of VILI test Positive	11
Images of VILI test positive, suspicious of cancer	11
<b>Chapter 3: Treatment of VIA positive cases in the same visit: 'screen-and-treat' approach</b>	<b>12</b>
Algorithm for 'screen-and-treat' approach	13
Cryotherapy for the treatment of VIA positive lesions	14
Equipment and consumables required for cryotherapy	14
Steps of performing Cryotherapy procedure	15
Post-treatment care and follow up	15
Thermal-ablation (cold coagulation)	16
Equipment and consumables necessary for Thermal-ablation	16
Steps of Thermal-ablation procedure	16
Possible side effects	17
Post-treatment care and follow up	17
<b>Chapter 4: Referral of VIA positive cases not eligible for cryotherapy/Thermal ablation (screen and treat)</b>	<b>18</b>
Colposcopy	18
Common indications of colposcopy	18
<b>Annexures</b>	
Annexure-1: Sample consent form	19
Annexure-2: VIA test reporting format	20
Annexure-3: Training curriculum for VIA & cryotherapy/thermal ablation	21
Annexure-4: Eligibility criteria for VIA certification	23
Annexure-5: Skill Assessment Checklist for VIA test	24

ICMR-NICPR

## CHAPTER 1

### Visual inspection with acetic acid (VIA)

Visual inspection with acetic acid is naked-eye examination of the uterine cervix, after application of 5% acetic acid and interpreting the result after one minute. This is a simple and inexpensive test for the detection of cervical precancerous lesions and early invasive cancer. The results of VIA test are immediately available and do not require any laboratory support.

#### Principle of VIA test:

Acetic acid application on cervical epithelium causes reversible intracellular dehydration and coagulation of the protein within the cervical cells. The intensity of coagulation is dependent on amount of protein in the cell. As the dysplastic cells have more chromatin content, the coagulation is intense and cells turn white after application of acetic acid.

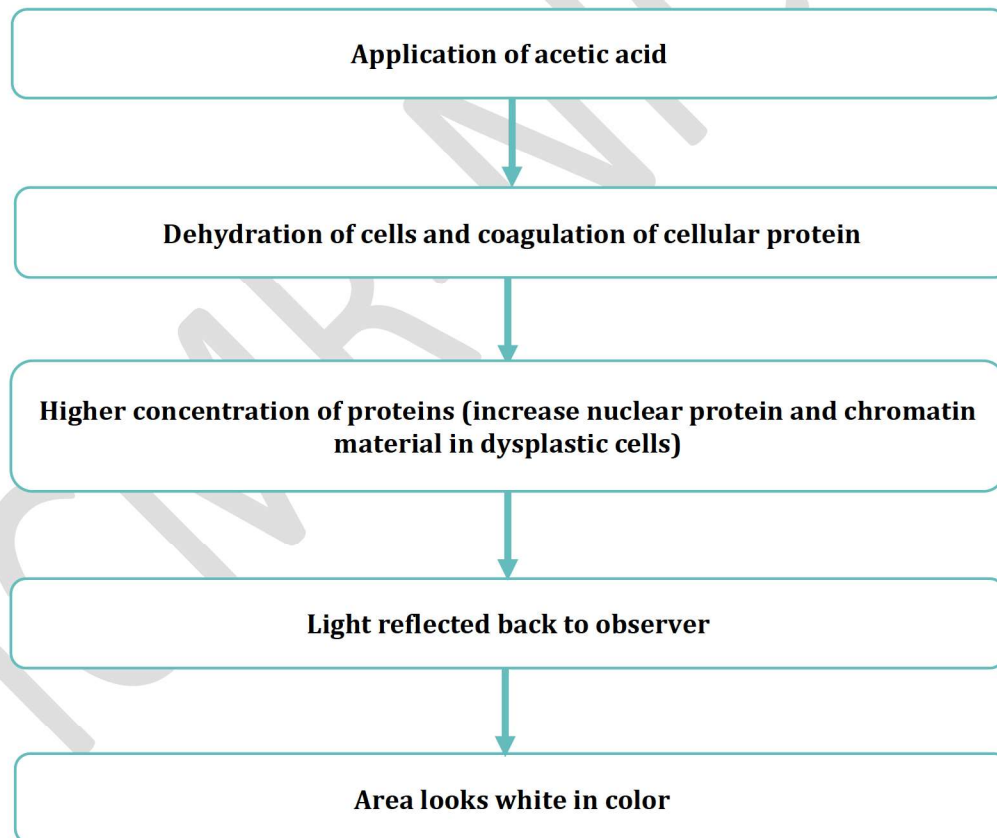


Fig: 1.1: Principle of VIA Test



A thorough understanding of the anatomy and physiology of the cervix is absolutely essential to understand the basics and to interpret the outcome of screening.

### **Gross anatomy of the uterine cervix:**

The cervix is the lowermost portion of the uterus, separating the body of the uterus from the vagina. The average length of the cervix is 3-4 cm. The cervix has two openings, internal os (opens in to endometrial cavity) and external os (opens in to vagina). In parous women, the cervix is bulky and the external os appears as a wide, gaping, transverse slit. In nulliparous women, the external os resembles a small circular opening. The endocervical canal, connects the uterine cavity with the vagina and extends from the internal to the external os. The stroma of the cervix is composed of dense, fibromuscular tissue which contain the vascular, lymphatic and nerve supplies to the cervix. The cervix receives the blood supply from cervical branch of uterine artery which descend in the lateral aspects of the cervix at 3 and 9 o'clock positions. The nerve supply is derived from the hypogastric plexus. The endocervix has extensive sensory nerve endings, while there are very few in the ectocervix (which makes the procedures done on the ectocervix less painful compared to that done in endocervix).

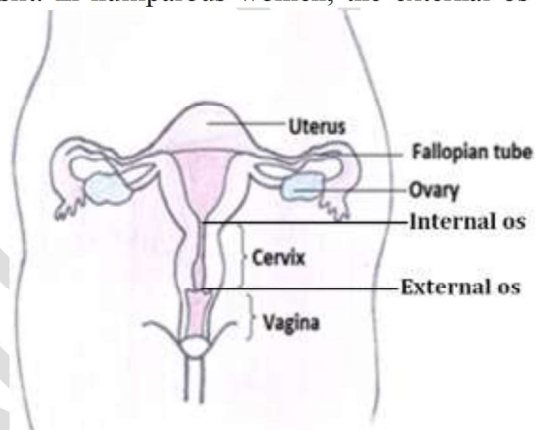


Fig. 1.2: Gross anatomy of the uterine cervix

### **Microscopic anatomy:**

Ectocervix is covered by a pink stratified squamous epithelium, consisting of multiple layers of cells and a reddish columnar epithelium consisting of a single layer of cells lines the endocervix. The intermediate and superficial cell layers of the squamous epithelium contain glycogen. The location of squamocolumnar junction in relation to the external os varies depending upon age, menstrual status, and other factors such as pregnancy and oral contraceptive use.

*Squamous metaplasia* in the cervix refers to the physiological replacement of the everted columnar epithelium on the ectocervix by a newly formed squamous epithelium from the sub-columnar reserve cells.

*Transformation zone* is the region of the cervix where squamous metaplasia occurs between the original and new squamo-columnar junction (Fig 1.3). Identifying the transformation zone is of great importance in cervical cancer screening, as almost all manifestations of cervical carcinogenesis occur in this zone. The squamocolumnar junction appears as a sharp line, due to the difference in the height of the squamous and columnar epithelium.

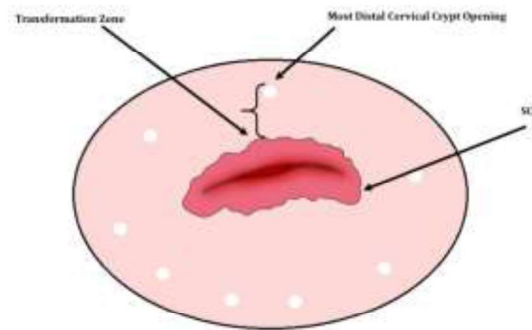


Fig 1.3: transformation zone

The location of the squamocolumnar junction in relation to the external os is variable over a woman's lifetime and depends upon factors such as age, hormonal status, birth trauma, oral contraceptive use and certain physiological conditions such as pregnancy. During childhood and perimenarche, the original squamocolumnar junction is located at, or very close to, the external os (Fig 1.4). After puberty and during the reproductive period, the female genital organs grow under the influence of estrogen. Thus, the cervix swells and enlarges and the endocervical canal elongates. This leads to the eversion of the columnar epithelium of the lower part of the endocervical canal on to the ectocervix. This condition is called ectopy, which is visible as a strikingly reddish-looking ectocervix on visual inspection (Fig 1.5). During menopause, due to lack of estrogen, the cervix shrinks and squamocolumnar junction is indrawn into the cervical canal (Fig 1.6).

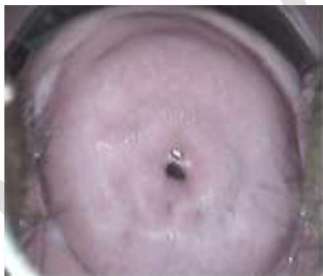

Fig 1.4 Childhood and perimenarche

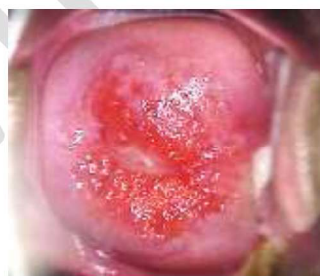

Fig 1.5 Reproductive age

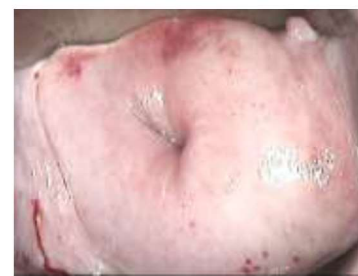

Fig 1.6 postmenopausal

### Instruments and materials required:

- Examining table
- Light source (white)
- Bivalve speculum, self-retaining speculum (Cusco)
- Instrument tray or container
- Distilled water/ boiled & cooled water
- Glacial acetic acid (100% acetic acid)
- Cotton-tipped -swab sticks
- Disposable gloves
- 0.5% chlorine solution for decontaminating
- Forms and registers for recording the findings

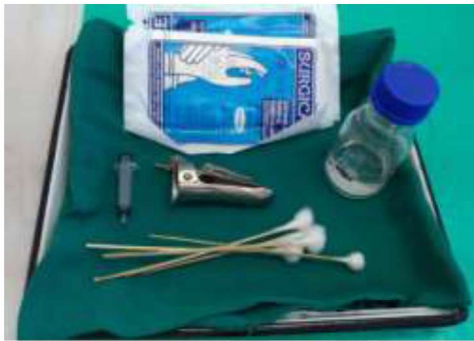

Fig 1.6: Consumables for VIA



Fig 1.7: White light source

### Preparation of 100 ml of 5% acetic acid:

**Acetic acid is to be freshly prepared every day.**

Ingredients	Quantity
1. Glacial acetic acid	5 ml
2. Distilled water	95 ml

**Preparation:** To prepare 100 ml of 5% acetic acid, carefully add 5 ml of glacial acetic acid into 95 ml of distilled water and mix thoroughly. To prepare lesser volume of 5% acetic acid, the proportion of glacial acetic acid and distilled water may be taken accordingly.

**Storage:** Unused acetic acid should be discarded at the end of the day. Only freshly prepared acetic acid is to be used every day. If not, the potency will be reduced and the lesions may be missed.

***Note: It is important to remember to dilute the glacial acetic acid, since the undiluted strength causes a severe chemical burn if applied to the epithelium.***



**Procedure of VIA test:**

- Explain the screening in detail to the woman. The woman should be reassured that the procedure is painless, and every effort should be made to ensure that she is fully relaxed and remains at ease during testing.
- Written informed consent should be obtained before screening (Sample consent form in annexure-1).
- The woman is requested to lie down in a modified lithotomy position on an examination table or couch.
- Gently introduce the speculum and open the blades of the speculum to view the cervix in the presence of good light source.
- Identify the external os, columnar epithelium (red in colour), squamous epithelium (pink) and the squamocolumnar junction.
- Identify the transformation zone. (Neoplastic changes occur in the transformation zone nearest to the squamocolumnar junction).
- Gently apply 5% acetic acid using a cotton swab soaked in acetic acid. The secretions should be gently wiped off. The swabs after use should be disposed of in the waste bucket.
- After removing the swab, carefully look at the cervix and check for any white lesions, particularly in the transformation zone close to the squamocolumnar junction, or dense, non-removable acetowhite areas in the columnar epithelium.
- The results of VIA test should be reported after one minute (Reporting before one minute may miss lesions that appear late). Note how rapidly the acetowhite lesion appears and then disappears.

**Carefully observe:**

- The intensity of the acetowhite lesion: if it is shiny white, cloudy-white, pale-white or dull-white.
- Speed with which the lesion appears after applying acetic acid. Lesions which appear immediately after application and stay for more than a minute, are more likely to be high grade lesion.
- The borders and demarcations of the white lesion: distinctly clear and sharp or indistinct diffuse margins; raised or flat margins; regular or irregular margins.
- Whether the lesions are uniformly white in colour, or the colour intensity varies across the lesion, or if there are areas of erosion (peeling of superficial epithelium) within the lesion.
- Location of the lesion:
  - ✓ Whether it is in or away from the transformation zone?
  - ✓ Is it touching the squamocolumnar junction? (which indicates it's a significant lesion)
  - ✓ Does it extend into the endocervical canal? (in that case, we cannot consider her for ablative therapy)
  - ✓ Does it occupy the entire, or part of, the transformation zone?
- Size (extent or dimensions) and number of the lesions.

**Reporting the outcome of VIA test****VIA negative**

VIA screening test is reported as negative in the case of any of the following observations:

- No acetowhite lesions are observed on the cervix.
- Polyps protrude from the cervix with bluish-white acetowhite areas (Fig 1.5)
- Nabothian cysts appear as raised areas which are button-like (Fig 1.6)
- Shiny, pinkish-white, cloudy-white, bluish-white, faint patchy or doubtful lesions with ill-defined, indefinite margins, blending with the rest of the cervix
- Streak-like acetowhitening is visible in the columnar epithelium.
- Ill-defined, patchy, pale, discontinuous, scattered acetowhite areas suggestive of squamous metaplasia (Fig 1.9)
- Multiple red spots visible on the cervix after application of acetic acid, that gives it an appearance commonly known as 'strawberry cervix' (Fig 1.10)
- Angular, irregular, digitating acetowhite lesions, resembling geographical regions, distant (detached) from the squamocolumnar junction (satellite lesions). (Fig 1.11)

- Dot-like areas are present in the endocervix, which are due to grapelike columnar epithelium staining with acetic acid. (Fig 1.12)
- Faint line-like or ill-defined acetowhitening is seen at the squamocolumnar junction (Fig 1.13).
- After the procedure, document the interpreted results in the standard format (Annexure-2)

#### Images for VIA test negative

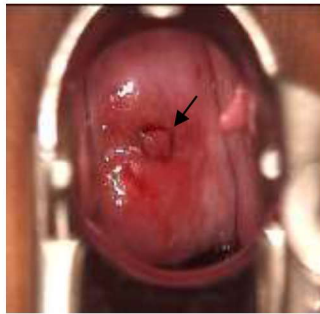


Fig 1.8: Polyp

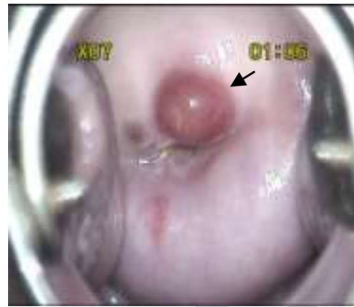

Fig 1.9: Nabothian cyst

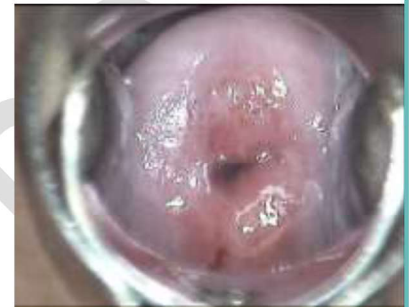

Fig 1.10: Mucus plug

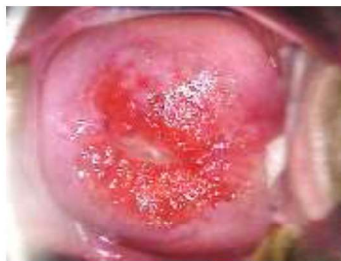

Fig 1.11: Ectopy

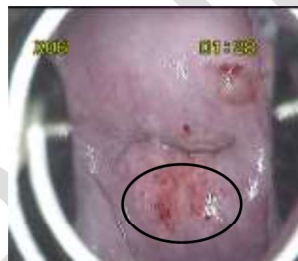

Fig 1.12: Squamous Metaplasia

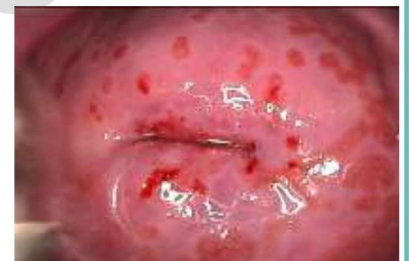

Fig. 1.13: Strawberry cervix suggestive of trichomonas vaginalis infection

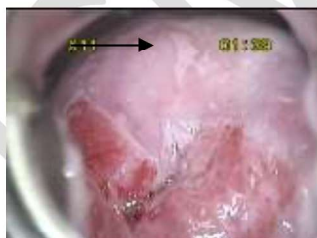

Fig 1.14: Satellite lesion

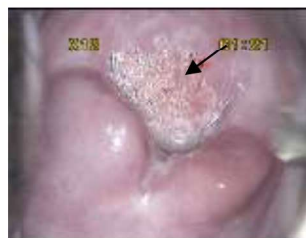

Fig 1.15: Columnar epithelium Staining with acetic acid

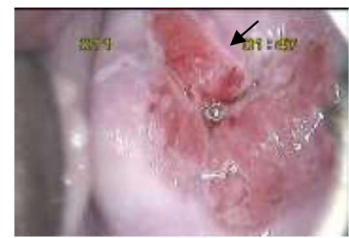


Fig. 1.16: Faint acetowhitening seen at the squamocolumnar junction



## VIA test positive (+)

The VIA test outcome is reported as positive in any of the following situations:

- There are distinct, well-defined, dense (opaque, dull- or oyster-white) acetowhite areas with regular or irregular margins, close to or abutting the squamocolumnar junction in the transformation zone or close to the external os if the squamocolumnar junction is not visible.
- Strikingly dense acetowhite areas are seen in the columnar epithelium
- The entire cervix becomes densely white after the application of acetic acid.
- Condyloma and leukoplakia occur close to the squamocolumnar junction, turning intensely white after application of acetic acid.

### Images for VIA test positive

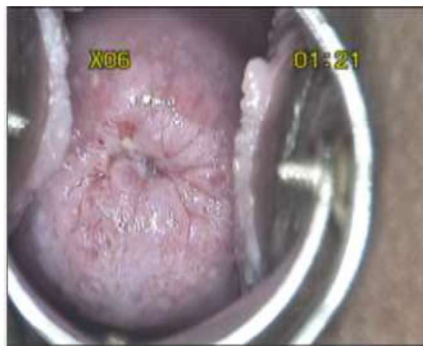

Fig: 1.17: Via Positive Circumferential

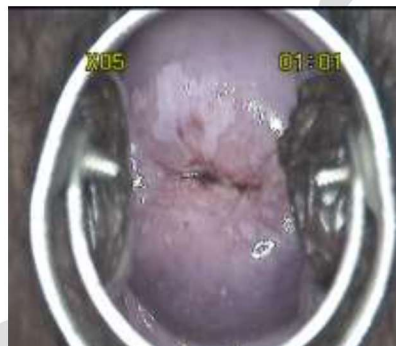

Fig: 1.18: VIA positive (11 to 12 o'clock)

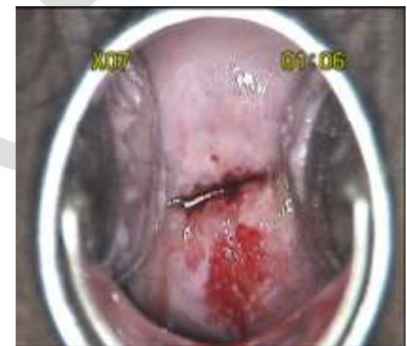

Fig: 1.19: VIA positive 11 to 1 o'clock & 4 to 7 o'clock

## VIA test positive, invasive cancer

The test outcome is scored as invasive cancer when:

- There is a clinically visible ulceroproliferative growth on the cervix that turns densely white after application of acetic acid and bleeds on touch

### Images for VIA test positive, invasive cancer

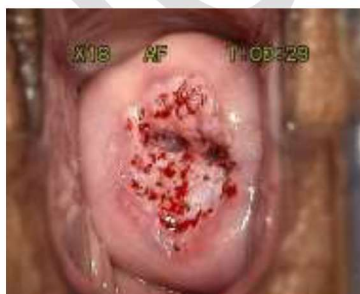

Fig: 1.20: Suspicious of Malignancy (dense white)

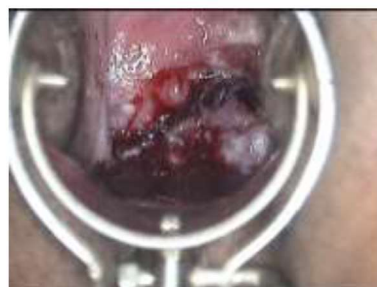

Fig: 1.21: Suspicious of Malignancy (growth, bleeds on touch)

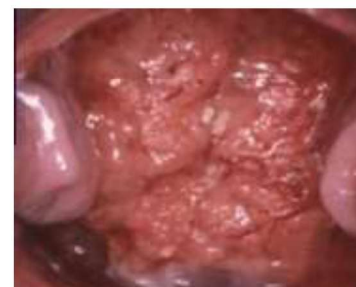

Fig: 1.22: Suspicious of Malignancy (growth)

## CHAPTER 2

### Visual Inspection with Lugol's Iodine (VILI)

Naked-eye visual inspection of the uterine cervix, after application of Lugol's Iodine as an adjunct to VIA test to confirm and delineate the abnormal lesion is called visual inspection with Lugol's iodine (VILI). VILI is not used as a primary screening test for cervical cancer screening.

#### Principle of VILI test:

The squamous epithelium contains glycogen. Since iodine is glycophilic, when applied to normal squamous epithelium, it turns mahogany brown or black in colour. But columnar epithelium and immature metaplastic cells does not contain glycogen, so it does not stain after the application of Lugol's iodine. The inflammatory cells either stain partially or do not stain.

The abnormal cells (cervical intraepithelial neoplastic cells) contain either less glycogen or no glycogen depending upon the degree of the lesion. So, these lesions do not stain brown after the application of iodine and becomes mustard yellow in colour.

#### Instruments and materials required:

Along with the instruments and materials that used for visual inspection of cervix with acetic acid, Lugol's iodine is required. It need not be prepared daily. It can be prepared at any facility or it can be purchased in ready to use form and it has a long shelf life.

#### Preparation of Lugol's iodine:

- Dissolve 10 g of potassium iodide in 100 ml distilled water.
- Add 5 g of iodine after the potassium iodide is fully dissolved.
- Stir well until all the iodine flakes have fully dissolved.
- The solution should be stored in a sealed amber glass container to prevent evaporation of iodine and loss of staining activity



Fig. 2.1 Commercially available Lugol's iodine

#### Procedure of VILI test:

After the VIA procedure, immediately after interpreting the VIA test result, apply Lugol's iodine to the cervix using a swab stick. Unlike VIA test, VILI test results can be interpreted immediately. If any VIA positive lesion present, that abnormal area will not stain iodine and will have mustard yellow colour.



## Reporting the outcome of VILI test:

### VILI test Negative-

- The cervical epithelium which stains brown (normal cervical epithelium) is termed as VILI negative
- VILI screening is reported as negative in the case of any of the following observations after iodine application:
  - A normal cervix; the squamous epithelium turns mahogany brown or black and the columnar epithelium does not change colour (Fig 2.1)
  - Patchy, indistinct, ill-defined, colourless or partially brown areas are seen.
  - Pale areas of no or partial iodine uptake are present on polyps (Fig 2.2)
  - A leopard-skin appearance is associated with *T. vaginalis* infection. (Fig 2.3)
  - Pepper-like non-iodine uptake areas are seen in the squamous epithelium, far away from the squamocolumnar junction
  - Satellite, thin, yellow, non-iodine uptake areas with angular, or digitating margins, resembling geographical areas, are seen far away from the squamocolumnar junction (Fig 2.6)
- If there is any isolated area is VIA negative yet does not stain iodine, then it is insignificant and such lesions are also considered VILI negative

### Images for VILI test Negative

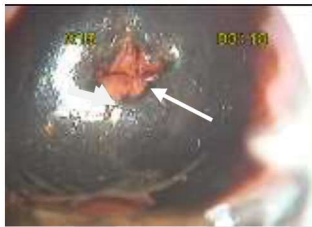

Fig: 2.1: VILI negative (columnar epithelium)

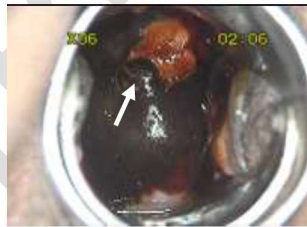

Fig: 2.2: VILI negative (Polyp)

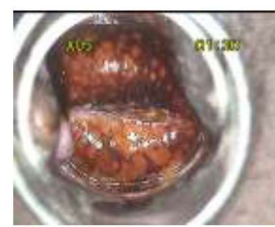

Fig: 2.3: VILI negative (leopard skin appearance- *T.V* infection)

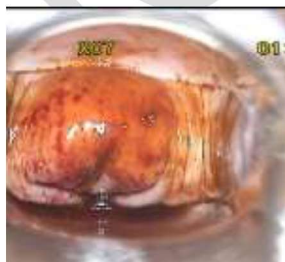

Fig: 2.4: VILI negative (post menopausal cervix)

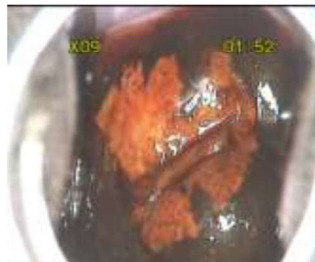


Fig: 2.5: VILI negative (Ectopy)

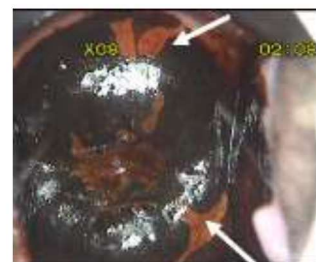


Fig: 2.6: VILI negative (Satellite lesion)

**VILI test Positive-** The outcome is scored as positive if dense, thick, bright, mustard-yellow or saffron yellow iodine non-uptake areas are seen in the transformation zone, close to or abutting the squamocolumnar junction or close to the os if the squamocolumnar junction is not seen or when the entire cervix turns densely yellow.

#### Images of VILI test Positive

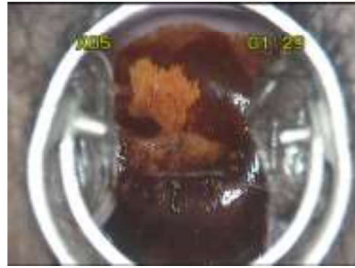

Fig: 2.7: VILI positive (12 o'clock position)

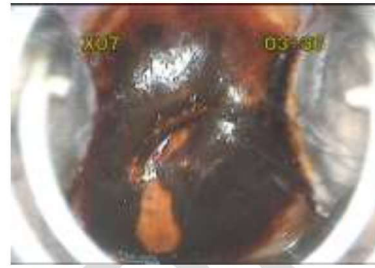

Fig: 2.8: VILI positive (7 o'clock position)

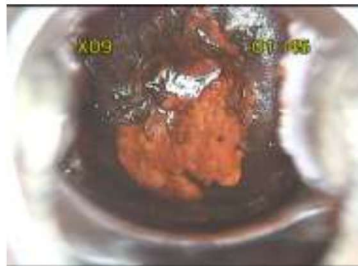

Fig: 2.9: VILI positive (3-8 o'clock position)

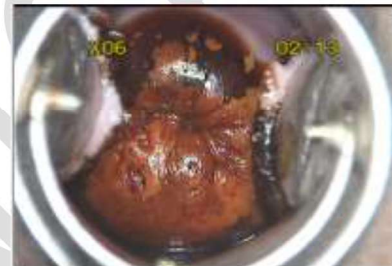

Fig: 2.10: VILI positive (Circum-oral)

**VILI test positive, invasive cancer:** Invasive cancer is reported when a frank, nodular, irregular, ulceroproliferative growth is visible on the cervix which turns densely yellow on application of iodine.

#### Images of VILI test positive, suspicious of malignancy

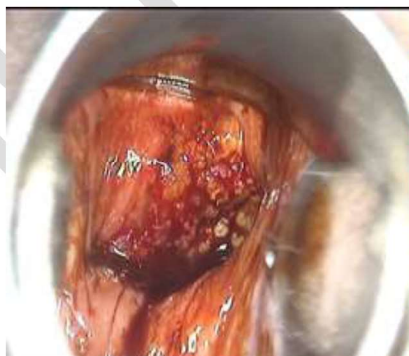

Fig: 2.11: VILI positive (suspicious of malignancy)

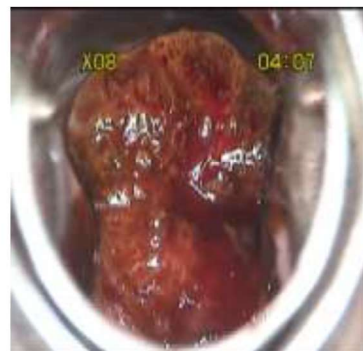


Fig: 2.12: VILI positive (suspicious of malignancy)

**Treatment of VIA positive cases in the same visit: 'Screen-And-Treat' approach**

Adding a diagnostic step after screening, before treatment of pre-cancer, can result in high loss to follow-up because additional patient visits are required as well as a longer time interval between screening and treatment. To reduce such loss to follow-up, the screen-and-treat approach has been developed and this strategy is increasingly being adopted worldwide. This approach eliminates the extra visits and time required for the diagnostic step.

VIA test-positive women are eligible for cryotherapy/Thermal ablation if

- Entire lesion is visible on ectocervix
- Lesion is not extending to the endocervical canal or to vagina
- Lesion is occupying less than 75% of the ectocervix
- There should be no evidence or suspicion of cancer or glandular abnormality

Women who are diagnosed as VIA test positives and who are eligible for ablative therapy as per the criteria mentioned above, could be treated using cryotherapy/thermal ablation in the same visit.

These women should be advised to come for follow up after one year to the health facility where VIA should be repeated during this follow up visit to check for the remission status.



### Algorithm for 'screen-and-treat' approach

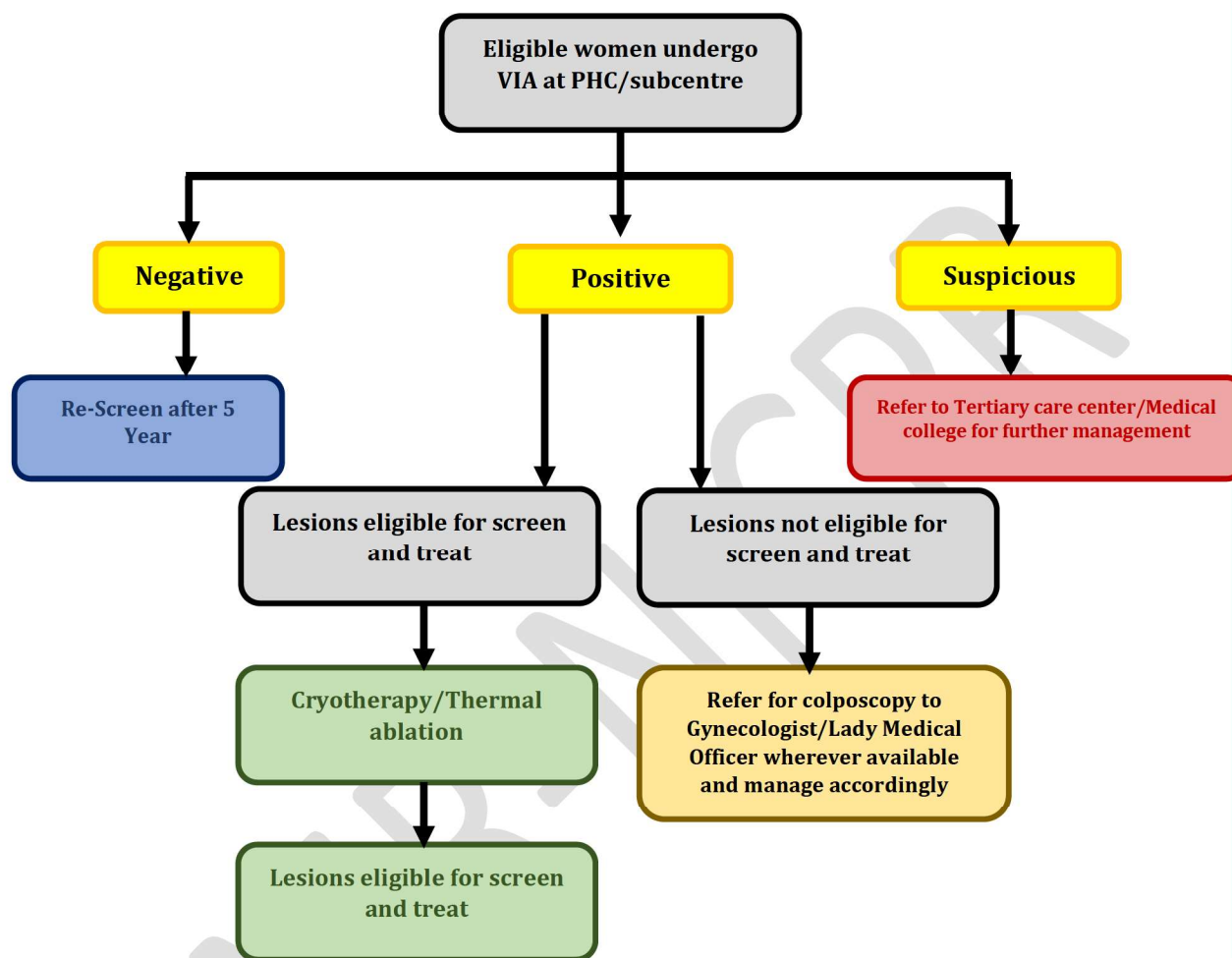


Fig: 3.1: Algorithm for 'Screen-and-treat' approach

### Cryotherapy for the treatment of VIA positive lesions

Cryotherapy is the freezing of the abnormal areas of the cervix by the application of a very cold probe. It takes only a few minutes and has no major side effects. The compressed gas like nitrous oxide ( $N_2O$ ) or carbon dioxide ( $CO_2$ ) is delivered on to the surface of ectocervix through specially designed probes known as cryoprobes. This procedure is safe and does not require anesthesia.



Fig. 3.2: Cryotherapy unit




Fig. 3.3: Probes



Fig. 3.4: Cryogun with probe

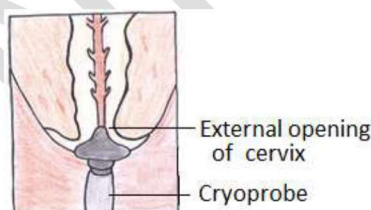


Fig. 3.5: Demonstration of positioning the probe

### Equipment and consumables required for cryotherapy procedure:

- Examination table
- Light source
- Self-retaining bi-valved vaginal speculum
- Disposable gloves
- Cotton swabs for wiping the cervix
- Normal saline solution
- Dilute Acetic acid (5%) solution (freshly prepared)
- Cryosurgery unit with adequate gas supply
  - ✓ Cryogun
  - ✓ Cryoprobes
  - ✓ Gas conveying tube
  - ✓ Pressure gauge
  - ✓ Gas cylinder connector

### Steps of performing Cryotherapy Procedure:

- Explain the procedure, and why it is important to return for further management as requested.
- Ensure that the woman has understood and obtain informed consent.
- Check the pressure inside the gas tank. It should be in the green zone as indicated in the pressure gauge of most of the cryotherapy models
- Insert the speculum gently and expose the cervix properly
- Apply 5% acetic acid to outline the abnormality and wait for a minute
- Choose an appropriate size cryoprobe that adequately covers the lesion
- Apply the cryoprobe tip at the external os of the cervix
- Ensure that the vaginal wall is not in contact with the cryoprobe or you may cause a freezing injury to the vagina
- Release the gas by pressing the trigger on the cryogun and hold it for 3 mins
- You will observe the ice forming on the tip of the cryoprobe and on the cervix. When the frozen area extends 4–5 mm beyond the edge of the cryoprobe, freezing is adequate
- Release the trigger and allow thawing for 5 minutes. Repeat freezing for 3 more minutes
- After second freezing, allow time for thawing. Do not pull cryoprobe till it comes out on its own
- Gently remove the cryoprobe and remove the speculum after careful inspection of the cervix.
- Examine the cervix for bleeding. If bleeding is noted, apply Monsel's paste. Do not pack the vagina
- Document treatment completion in individual case record form
- Provide her the date for next follow up and emphasize on the importance of it.

#### **Post-treatment care and follow up**

- Provide a sanitary pad
- The woman should be told that she may experience excessive watery discharge for up to 4 weeks. She should not get worried about it.
- Instruct the woman to abstain from intercourse for 4 weeks.
- Avoid douching or use of tampon for 4 weeks
- Inform her of possible complications and ask her to return immediately if she notes any of the following:
  - ✓ Fever with temperature higher than 38 °C lasting for more than 48 hrs.
  - ✓ Severe lower abdominal pain
  - ✓ Foul-smelling or pus-like discharge
  - ✓ Bleeding for more than two days or bleeding with clots
- To report for follow up after 6 months



### **Thermal-ablation (Cold coagulation)**

Thermal ablation is a safe and acceptable procedure used as an alternative to cryotherapy for treatment of VIA positive lesions. A probe heated to 100°C destroys the abnormal lesions by direct contact the of the ectocervix (destructive therapy), and does not require anesthesia. Multiple overlapping applications may be used to cover the entire lesion.




Fig. 3.6: Thermocoagulator



Fig. 3.7: Thermocoagulator Probe

### **Equipment and consumables necessary for Thermal-ablation:**

Thermocoagulation unit (as shown in the figure above)

- Metallic probe
- Wire for electrical connection
- Light source
- Instrument tray containing
  - ✓ Self-retaining bivalve speculum
  - ✓ Disposable gloves
  - ✓ Sterile cotton swabs, cotton tipped swabs
  - ✓ Dilute Acetic acid (5%) solution (freshly prepared)

### **Steps of Thermal-ablation procedure**

- Expose the cervix gently using the self-retaining speculum
- Focus light source for clear visualization of cervix
- Apply 5% acetic acid to outline the abnormality and wait for a minute
- Set the Thermocoagulator at 100°C
- Apply the heated thermocoagulator probe on the area to be treated on ectocervix and heat for 45 seconds at 100°C

- Switch off the thermocoagulator unit and gently remove the probe taking care not to touch the vulva or vagina with the probe
- Remove the speculum after careful inspection of the cervix. Do not pack the vagina
- Document treatment completion in individual case record form
- Provide her the date for next follow up and emphasize on the importance of it.

**Possible side effects:** Thermal ablation is well tolerated. However following symptoms may be experienced rarely:

- Mild pelvic pain.
- Watery discharge, spotting or light bleeding for 2-4 weeks.
- Other side effects are rare. (Infection, very rarely cervical stenosis)

**Post-treatment care and follow up:**

- Provide a sanitary pad
- The woman should be told that she may experience excessive watery discharge for up to 2- 4 weeks. She should not get worried about it.
- Instruct the woman to abstain from intercourse for 4 weeks.
- Avoid douching or use of tampon for 4 weeks
- Inform her of possible complications and ask her to return immediately if she notes:
  - Fever with temperature higher than 38 °C lasting for more than 48 hrs
  - Severe lower abdominal pain
  - Foul-smelling or pus-like discharge
  - Bleeding for more than two days or bleeding with clots
- To report for follow up after 6 months

***Note: Do not perform ablative therapy if the patient is***

- menstruating at the time of the procedure
- Pregnant (to be treated after 6 weeks of child birth)
- Suffering from any genital tract infection(treat the infection before the procedure)

## CHAPTER 4

### Referral of VIA test positive lesions not eligible for cryotherapy/thermal ablation

Lesions which are not amenable for treatment by ablative methods using cryotherapy or thermal ablation should be referred to the nearest facility where gynecologist is available for performing colposcopy.

#### Colposcopy

Colposcope is an instrument that uses a light and a low-powered microscope to make the cervix appear much larger and has a powerful light source for illumination of the area to be examined and a variable magnification ranging from 4 times to 25 times. Colposcopy is a procedure that involves examination of the cervix, vagina and vulva with the help of Colposcope. Colposcopy helps in differentiating between normal, benign and cancerous lesions of cervix, directing biopsy from the suspicious area on the cervix and in taking treatment decisions.

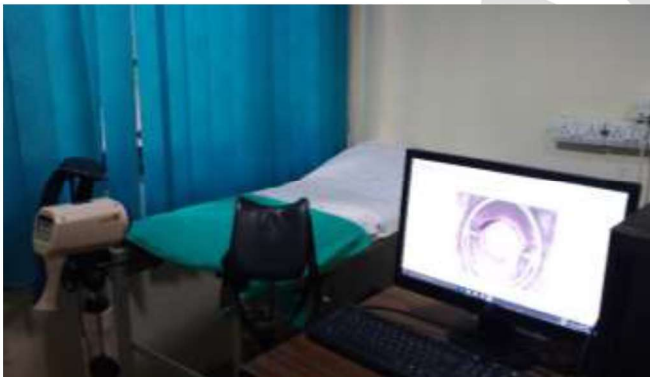


Fig. 4.1: Video colposcope

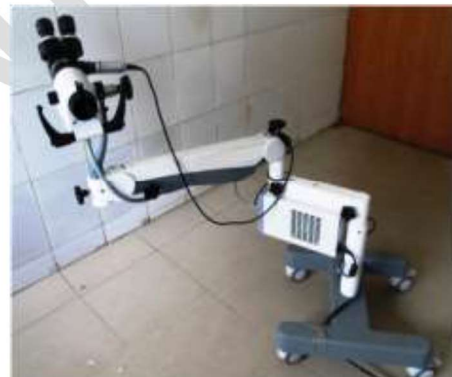

Fig. 4.2: Binocular colposcope

#### Common indications of Colposcopy procedure:

- Positive VIA test or any other cervical cancer screening test
- Suspicious looking cervix
- Confirmation of lesions prior to treatment
- Women with symptoms suggestive of invasive cancer eg, postcoital bleeding, postmenopausal bleeding, menorrhagia, irregular PV bleeding etc
- Follow up of women after treatment



**Sample Consent Form for VIA**

I have been explained in detail about the VIA test for prevention and early detection of cancer in the mouth of my womb (uterine cervix) . The advantages and the purpose of these tests have been clarified to me.

I understand that the mouth of my cervix will be examined after application of 5% acetic acid to detect or to exclude pre cancer or cancer. I understand that these procedures are generally harmless, but may occasionally cause some irritation or mild bleeding, which can be easily controlled.

I understand that, if the VIA test is positive, I might have to undergo further tests to confirm and I will be managed accordingly.

I understand that a negative screening does not rule out the possibility of developing these diseases later. I need to contact the health facility at the earliest, whenever I have any symptoms/warning signs/complaints listed in the IEC materials provided and explained to me. I hereby express my willingness to undergo the above tests and treatment, if advised.

Signature of the individual:

Name:

Date:

Screening ID:

Address:

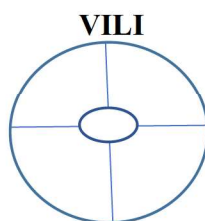
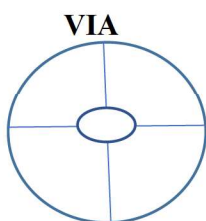
Health care provider's name & signature

Date:

## VIA Reporting Chart

1. Screening ID: \_\_\_\_\_ 2. Name: \_\_\_\_\_
3. Age: \_\_\_\_\_ 4. Center name \_\_\_\_\_
5. District \_\_\_\_\_ 6. Date of visit: \_\_\_\_ / \_\_\_\_ / \_\_\_\_ (Day/Month/Year)
7. Parity \_\_\_\_\_
8. Do you have any of these following symptoms? (Tick whichever is applicable)
- |   |  |
|---|--|
| a) Excessive vaginal discharge region       | e) Itching in the external anogenital region |
| b) Ulcers in the external anogenital region | f) Lower abdominal pain                      |
| c) Pain during sexual intercourse           | g) Bleeding after intercourse                |
| d) Intermenstrual bleeding                  | h) Low back ache                             |
9. Visual examination findings (per speculum) (Tick whichever is applicable)
- |                                       |                   |
|---------------------------------------|-------------------|
| a) Squamocolumnar junction fully seen | e) Cervical polyp |
| b) Nabothian follicles                | f) Cervicitis     |
| c) Leukoplakia                        | g) Condyloma      |
| d) Growth                             |                   |
10. Findings one minute after application of 5% acetic acid (VIA)
- VIA Negative
  - VIA Positive
  - invasive cancer
11. In case of VIA positive lesion, does the acetowhite lesion extend into the endocervical canal? (Skip this question in case of VIA negative)
- Yes
  - No
12. In case of VIA positive lesion, number of quadrants involved
- One
  - Two
  - Three
  - Four
13. Findings after application of Lugol's iodine (VILI)
- Negative
  - Positive
  - invasive cancer

14. Draw the location of VIA positive & VILI positive



Signature of the health care provider



## Training curriculum for VIA &amp; Cryotherapy

## Trainees: Staff nurses and ANMs

DAY 1		
	Topic	Duration
Theory sessions	Pre-training knowledge assessment	15 mins
	Goals and objectives of the training	30 mins
	Introduction to Universal Screening of Common NCD	30 mins
	Key tasks of Staff nurses and ANMs in cervical cancer prevention	30 mins
	Rationale for screening, target age group; risk factors, signs and symptoms, etiopathogenesis of cervical cancer	45 mins
	Natural history of cervical cancer	30 mins
Practical sessions	Anatomy of female reproductive organs in relation to cervix (using model)	1 hour
	Per speculum examination using pelvic model	2 hours
	Summary of the day	30 mins
DAY 2		
	Recap of Day 1	30 mins
	HPV and cervical cancer	30 mins
	Counselling for cervical cancer screening	30 mins
	Video demonstration of per speculum examination to visualize the cervix	30 mins
	Pictures of normal variants of cervix	30 mins
	VIA procedure and principle of test	30 mins
Practical sessions	Preparation of 5% acetic acid	30 mins
	Demonstration of VIA on women by the trainer (observation of the procedure)	2 hours 30 mins
	Summary of the day	30 mins
DAY 3		
	Recap of Day 2	30 mins
	Equipment, supplies, infection prevention items and preparing the woman	30 mins
	Demonstration of preparing 0.5% Chlorine solution	30 mins
	Practice in small groups: Counseling for cervical cancer screening	1 hour 30 mins
	Supervised demonstration of VIA in the gyne OPD, gyne ward and cervical cancer screening clinic (Trainer guides the trainees one by one to carry out VIA test)	3 hours 30 mins
DAY 4		
	Recap of Day 3 (trainee will be asked about the ease of VIA procedure).	30 mins
	Interpreting results of VIA	1 hour
	Documenting results of VIA	30 mins
	Pictures of positive VIA test	45 mins
	VIA positive, what next?	45 mins
	Hands-on demonstration of VIA in women (done by trainees under supervision)	3 hours

DAY 5		
	Recap of Day 4	30 mins
	Principle of VILI	30 mins
	Confirmation of VIA positives with VILI	30 mins
	Skills Practice in classroom <ul style="list-style-type: none"> <li>▪ Counseling for screening for cervical cancer</li> <li>▪ Getting consent from women undergoing the test</li> <li>▪ Screening cervix with VIA</li> </ul>	2 hours
	Hands-on demonstration of VIA in women (done by trainees under supervision)	3 hours
DAY 6		
	Supervised practice of performing per speculum examination and VIA on model using checklist	1 hours
	Video demonstration of positive VIA and VILI	30 mins
	Slideshow of positive VIA and VILI pictures	1 hour
	Independent practice of VIA test on women	2 hours
	Role play by trainees on counselling women for cervical cancer screening	2 hours
DAY 7		
	Overview of Cryotherapy system and step-by-step approach to cryotherapy	1 hour
	Cryotherapy equipment	30 mins
	Demonstration cryotherapy on model (apple, potato etc)	2 hours
	Side effects of cryotherapy procedure	30 mins
	Pre-cryotherapy counselling	30 mins
	Post cryotherapy advice/instructions	30 mins
	Independent practice of VIA test on women	1 hour 30 mins
DAY 8		
	Review Cervical Images	30 mins
	Practice VIA, Cryotherapy on models	1 hour
	Hands-on VIA on women in OPD/ward	2 hours
	Hands-on cryotherapy on VIA positive women	3 hours
DAY 9		
	Addressing/answering women's concerns regarding cervical cancer screening (Role play by trainees)	2 hours
	Sterilization of instruments used during screening	1 hour
	Hands-on VIA on women in OPD/ward	3 hours 30 mins
DAY 10		
	Post-training knowledge assessment	30 mins
	Post training skill assessment using the checklist	1 hour 30 mins
	Certificate distribution	30 mins
	Feedback from the trainees	<b>30 mins</b>

### Eligibility criteria for VIA certification

**The recommended number of procedures to be performed by the trainee during the training period are as follows:**

**VIA-100**

- Observed -20
- Supervised practice- 30
- Independent practice-50

**Cryotherapy/Thermal ablation-10**

- Observed -5
- Supervised practice- 2
- Independent practice-3

***Note: The trainee needs to score at least 70% in the knowledge and 80% in the skills assessment (Annexure-4) at the end of the training to be certified as competent***



### Skill Assessment Check list for VIA test

**Note for the Trainer:** Give the score of '1' against each task done satisfactorily and '0' for tasks not done or not done satisfactorily. Add the total score and total score % achieved by the participant. To be competent in the skill, the participant must score  $\geq 80\%$ .

Checklist for VIA Counseling and Clinical Skills					
Step/Task	Cases				
Pre-VIA Counseling	1	2	3	4	5
1. Greet woman respectfully and with kindness					
2. If cancer screening counseling not done, counsel woman prior to performing VIA test					
3. Assess woman's knowledge about cervical cancer and VIA test					
4. Respond to woman's needs and concerns about cervical cancer and the VIA test					
5. Describe the procedure and what to expect					
<b>Getting Ready</b>					
6. Check that supplies and light source are available and ready for use					
7. Check that the woman has emptied her bladder					
8. Have the woman undress from waist down. Help her get on to the examination table and drape her					
9. Wash hands thoroughly with soap and water and air dry them.					
10. Put one pair of new examination gloves on both hands					
11. Arrange instruments and supplies					
<b>Visual Inspection with Acetic Acid</b>					
12. Insert speculum gently and fix blades so that entire cervix can be seen clearly					
13. Move light source so cervix can be seen clearly					
14. Check the cervix for cervicitis, ectopy, tumors, nabothian cysts or polyp and clean cervix with normal saline if necessary. Disposing off the cotton swab as per guidelines.					
15. Identify the cervical os, Squamo-columnar junction (SCJ) and transformation zone					
16. Apply 5% acetic acid to cervix with a swab on a stick and wait 1 minute. Disposing off the cotton swab as per guidelines.					
17. Check if cervix bleeds easily. Check for any raised and thickened white plaques or acetowhite lesion in epithelium					
18. Remove any remaining acetic acid from the cervix and vagina with a swab. Disposing off the cotton swab as per guidelines					

19. Remove speculum gently and place it in 0.5% chlorine solution for 10 minutes for decontamination					
<b>POST-VIA TEST TASKS</b>					
20. Wipe light source with 0.5% chlorine solution or alcohol					
21. Immerse all used instruments in 0.5% chlorine solution for 10 minutes for decontamination					
22. Wash both hands with soap and water and air dry					
23. Record the VIA test results and other findings in caserecord					
24. Discuss the results of VIA test and pelvic examination with the woman and answer any questions <ul style="list-style-type: none"> <li>▪ If VIA test is negative, tell her when to return for repeat VIA after 5 years</li> <li>▪ If VIA test is positive and eligible for ablative therapy, discuss screen and treat option with cryotherapy/thermal ablation</li> <li>▪ If VIA test is positive, not eligible for ablative therapy or suspicious for cancer, refer her to higher appropriate facility for management</li> </ul>					
<b>POST-VIA TEST COUNSELING</b>					
25. Assure woman that she can return for advice or medical attention any time					
26. Provide follow-up instructions					
<b>Total Score</b>					
<b>Total Score %</b>					

**Result:** Circle the appropriate result based on the score and score% achieved.

**Pass**                      **Needs Improvement**

ICMR-NICPR